

Aortic fat pad and atrial fibrillation: cardiac lymphatics revisited

Ryszard W. Lupinski

Department of Cardiothoracic Surgery, Waikato Hospital, Hamilton, New Zealand

Key words

aortic fat pad, atrial fibrillation, cardiac lymphatics, Fontan procedure.

Abbreviations

AF, atrial fibrillation; AV, atrioventricular; LPLT, left principal lymphatic trunk; MPA, main pulmonary artery; RPLT, right principal lymphatic trunk; SA, sinoatrial.

Correspondence

Dr Ryszard W. Lupinski, Department of Cardiothoracic Surgery, Waikato Hospital, Salwyn Street, Hamilton 3206, New Zealand.
Email: rlupinski@yahoo.com.sg

R. W. Lupinski PhD.

Accepted for publication 23 May 2008.

doi: 10.1111/j.1445-2197.2008.04802.x

Abstract

The lymphatics of the heart have not generated any broad or sustained interest among clinicians. Few publications on cardiac lymphatics are available, the anatomy is not routinely known and the true role of cardiac lymphatics remains doubtful. One important anatomical concept needing clarification is that of the lymphatic drainage of conduction tissue. The sinoatrial node lymphatic collector and right principal lymphatic trunk are both incorporated into the aortic fat pad of the ascending aorta and are the most frequently damaged lymphatic vessels during cardiac surgery. Thus, preservation of the aortic fat pad and its lymphatic collectors should reduce the incidence of new atrial fibrillation observed in patients after cardiac surgery. This review assesses current knowledge of cardiac lymphatics and shows their possible role in triggering arrhythmias in the postoperative period.

Introduction

The lymphatic system of the heart consists of three subdivisions (plexuses) as well as the lymphatic drainage of conduction tissue and the main collecting lymph channels or principal lymphatic collectors. The main collecting channels drain lymph into the mediastinal lymph nodes and from there to the thoracic duct and back into the circulation.¹ Fat pads are the fibro-adipose structures found within the epicardium. The presence of neurogenic tissue in the aortic fat pad of humans is believed to be responsible for extracardiac integration of autonomic control of cardiac function.² However, one epicardial fat pad – the aortic fat pad – is the subject of interest in this manuscript as it contains lymphatic vessels: the sinoatrial (SA) node lymphatic collector and the right principal lymphatic trunk (RPLT).³ Recent clinical studies have shown that preservation of the aortic fat pad significantly decreases the incidence of postoperative atrial fibrillation (AF).⁴

Anatomy

The subendocardial plexus

This is a plexus of small lymphatic capillaries derived from endothelium and basal membrane. Enormous dilatation reserve and scarce distribution characterize the lymphatic capillaries; one lymphatic capillary accounts for 1300 blood capillaries. They form a branching and anastomosing network, lying in the subendocardial connective tissue layer of all four cardiac chambers. The subendocardial plexus drains into the myocardial plexus through small channels that have no characteristic pattern.

The myocardial plexus

This is a more voluminous plexus of lymphatic capillaries throughout the myocardium. They form a basket-like network and lie close to the blood capillaries in the interstitial spaces. They drain into larger

lymphatic channels that follow the arterioles to the interstitial connective tissue septa. From here they drain the lymph towards the epicardium.

The epicardial plexus

The epicardial plexus drains the myocardial and subepicardial plexuses of lymphatic vessels and it is a very loosely arranged plexus in the subepicardial connective tissue. These small lymphatic channels (lymphatic precollectors) form a superficial plexus and drain into the deep plexus of lymphatic channels of larger-sized lymphatic collectors. Lymphatic collectors run on the surface of the heart and unite into principal lymphatic collectors. The superficial plexus in pathological conditions can communicate with the pericardium to create dense adhesions.

The heart valves

Lymphatic vessels can be found on the atrial surface of the mitral valve as well as the tricuspid valve; they have not been observed on aortic or pulmonary valves.

Lymphatic drainage of conduction tissue

Sinoatrial node

Lymphatic capillaries are found mostly in the superficial layers of the node, surrounded by collagenous fibres and cells of the conduction tissue. The SA node contains many more blood vessels than lymphatics. Lymphatic vessels from the SA node drain into the subepicardial lymphatic network of the right atrium, and lymph from there flows to the RPLT. There are two main routes of lymph drainage from the SA node: either directly through the SA node collector (Fig. 1) to the RPLT or turning around the right atrial appendage and running on its posterior edge towards the RPLT located between the aorta and the main pulmonary artery (MPA) (Figs 1,2).³

AV node and AV bundle (space of Curran)

The atrioventricular (AV) node and AV bundle are surrounded by a fibrous sheath, which was first described in 1906, and its lymphatic nature was reported 3 years later. Between the fibrous sheath and the bundle itself is a prominent space (space of Curran) that is conspicuous enough in mammalian hearts so that a needle can be placed into it for injection of contrast medium. The fibrous sheath and its space of Curran extend along the main branches of the AV bundle, as well as in various degrees along the subendocardial and intramyocardial arborization plexuses of the conduction system. This allows observation of the AV and ventricular portions of the conduction system by injection of a dye.⁵ It was found that the fibrous sheath contains a small amount of clear fluid that protects the conduction tissue against mechanical injury during contractions. It took another 70 years to describe the lymphatic drainage pathways from the AV node and AV bundle; the drainage goes mainly to the left principal lymphatic trunk (LPLT) (Fig. 2).^{3,6,7}

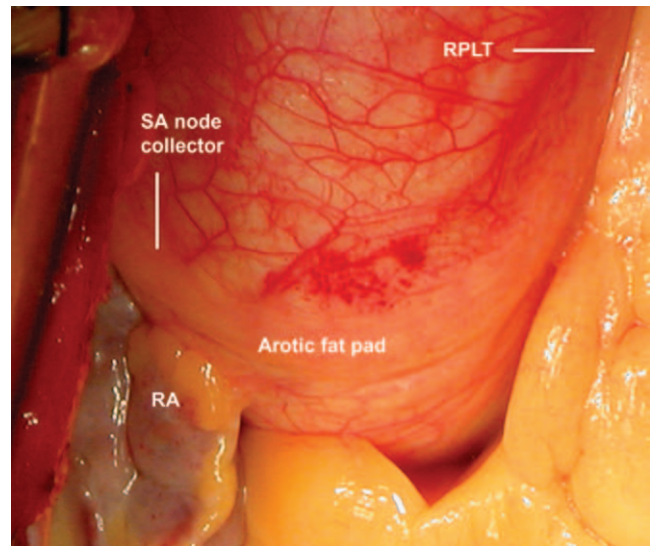


Fig. 1. Aortic fat pad and its lymphatic collectors: the sinoatrial (SA) node collector and the right principal lymphatic trunk (RPLT). Note the red network of blood capillaries within ascending aorta and bloodless aortic fat pad, as lymphatics do not contain erythrocytes. RA, right atrium.

Main lymphatic vessels of the heart

All lymphatic vessels draining the subepicardial, myocardial and subendocardial plexuses unite in a principal lymphatic trunk. The LPLT collects lymph from the left branch (anterior surface of the left ventricle), right branch (posterior surface of the left ventricle and left atrium) and the AV node and AV bundle. Left and right branches unite under the left atrial appendage into the LPLT, which goes behind and along the left pulmonary artery, crosses the top of the left coronary artery and passes to the left of the aortic root and ascending aorta toward the aortic arch. The RPLT collects lymph from the right ventricle, right atrium and SA node. On the posterior surface of the heart it runs along the interventricular groove towards the base of the heart and AV groove. Then, like right coronary artery, it turns towards anterior surface of the right ventricle and goes along AV groove towards the right atrial appendage and then towards the ascending aorta. From here, it goes towards aorticopulmonary window to join the LPLT and to form the principal lymphatic channel. The principal lymphatic channel runs behind the MPA and the aorta towards the mediastinal lymph nodes. The principal lymphatic channel drains into the lymph nodes of the ligamentum arteriosum (para-aortic or aorticopulmonary window group of lymph nodes) or the cardiac lymph node that can be found either within the anterior superior mediastinal lymph nodes, subcarinal lymph nodes or right paratracheal lymph nodes.^{1,7,8} Then cardiac lymph mixes with lymph from the lung and drains into the thoracic duct on the left side of the chest and on the right into the right thoracic duct. The right thoracic duct connects with the cervical and head lymphatics to

join the thoracic duct and hence into the bloodstream. Lymphatic connections between the heart and remote organs situated below the diaphragm through oesophageal, aortic and diaphragmatic channels have been described.

Role of cardiac lymphatics

Lymph is a product of the capillary permeability in the heart and is composed of protein particles, debris from tissue injury and leucocytes. It does not contain red cells or platelets and it has the appearance of a clear fluid. The main role of the cardiac lymphatics is to protect the interstitial space against tissue swelling and this role is achieved by: absorption and transportation of protein, water and electrolytes from the tissue space back into the circulation; control of tissue volume and tissue pressure; removal of debris from injured tissue; protection against mechanical injury of conduction tissue; and absorption of fluid from the pericardial space.¹ All these functions are compromised if cardiac lymphatic drainage is reduced or disrupted and it may lead to cardiac lymphostasis.

Cardiac lymphostasis

Injury of lymphatic collectors results in impairment of lymphatic drainage and to cardiac lymphostasis within the area of the injured lymphatic vessel. If the damage is small, the signs of cardiac lymphostasis are minimal or absent.^{1,9} If one or both principal lymphatic trunks are damaged, the physiological function of cardiac lymphatics is compromised. Interstitial pressure rises as tissue debris and protein particles cannot re-enter the circulation and tissues become swollen. Cardiac lymphostasis has a characteristic electrocardiographic appearance. It mimics coronary ischaemia with Q waves, ST changes and T-wave abnormalities on electrocardio-

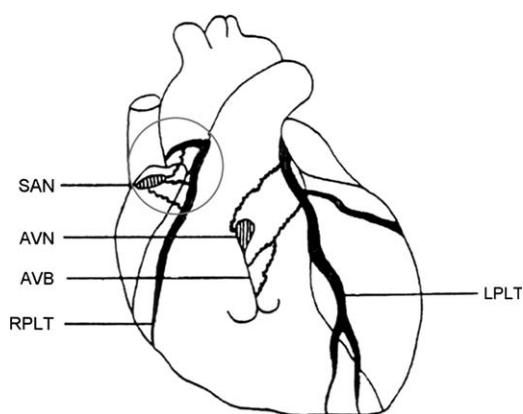


Fig. 2. Lymphatic drainage of conduction tissue. Encircled area includes the ascending aorta and lymphatic drainage of the sinoatrial node. AVB, atrioventricular bundle; AVN, atrioventricular node; LPLT, left principal lymphatic trunk; SAN, sinoatrial node; RPLT, right principal lymphatic trunk.

grams.^{10,11} Angiograms carried out on patients with lymphostasis show unobstructed blood flow in the coronary vessels.¹⁰ However, some tissue samples taken from the heart for histopathological evaluation have shown extrinsic compression of the coronary arteries.^{11,12} Tachyarrhythmias are common and bradyarrhythmias are also observed when lymphatic drainage from the heart is compromised.^{10,11}

Common sites of lymphatic injury in cardiac surgery

Obstruction of cardiac lymphatics takes place during almost all open-heart operations where a cross-clamp is applied to the aorta and the RPLT is crushed for the duration of the operation (Fig. 3). In cases where a cross-clamp is applied to the aorta and pulmonary artery, the right and LPLT are obstructed. These lymphatic channels are delicate structures (particularly the right lymphatic trunk) and long aortic cross-clamp procedures may lead to irreversible injury of these vessels. SA node collectors are also frequently damaged during preparation of the right atrial appendage for venous cannulation for cardiopulmonary bypass (Fig. 3, C). The aortic fat pad, which contains another SA node collector, will probably be damaged during coronary artery bypass grafting (Fig. 3, A). This area is the site of either proximal anastomosis of the venous graft or insertion of the needle to deliver antegrade cardioplegia. Aortotomy for aortic valve replacement also carries a high risk of SA node collector injury. Compromised postoperative lymphatic drainage from the SA node is responsible for its dysfunction and it may trigger supraventricular arrhythmias in the perioperative period, which are frequently observed in such patients. Intraoperative damage of cardiac lymphatics may also take place during the Fontan procedure. An important part of this procedure, transection of the MPA just above the level of the pulmonary valve (Fig. 3, B, dotted line), is almost always associated with injury of both main lymphatic trunks, as they are anatomically incorporated into the MPA adventitia and run along the vessel. Common complications observed in patients after a Fontan procedure are difficult-to-control arrhythmias and prolonged pericardial or pleural effusions or 'swollen heart'. In other congenital corrective operations where the MPA is part of the reconstructive procedure (Rastelli procedure, tetralogy of Fallot and pulmonary stenosis/atresia), the principal lymphatic trunks can be easily damaged. During these operations, special care should be taken when dissecting and mobilizing the MPA for reconstruction of the right ventricular outflow tract. It may lead to similar complications to those observed after the Fontan procedure.

How does the heart deal with interruption of lymphatic drainage?

Communications have been described between vein and lymphatic capillaries (lymphaticovenous anastomoses) that reopen in the event

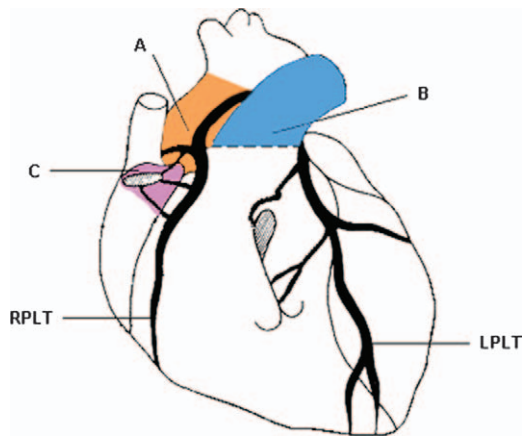


Fig. 3. Sites of possible damage to lymphatic collectors during cardiac surgery. Ascending aorta, A, proximal anastomosis of bypass graft, antegrade cardioplegia, aortic cannulation, aortic cross-clamp. Main pulmonary artery, B, transection during Fontan procedure (dotted line), reconstruction of main pulmonary artery in patients with right ventricular outflow tract obstruction (Rastelli procedure, repair of tetralogy of Fallot, pulmonary stenosis/atresia). Right atrial appendage, C, routine venous cannulation for cardiopulmonary bypass, part of Fontan procedure, transposition of the great arteries. LPLT, left principal lymphatic trunk; RPLT, right principal lymphatic trunk.

of surgically obstructed cardiac lymph outflow.^{8,9} However, current evidence does not indicate that these shunts play an important physiological role in cardiac lymph obstruction. Regeneration of lymphatic vessels and re-establishment of lymphatic integrity (lymphatic capillaries and collectors) takes 2–20 weeks.^{8–10} With time, the myocardium may show signs of irreversible damage including necrotic changes, fibrosis and scarring.^{9–11} In total disruption of lymphatic drainage, failure to drain excess interstitial fluid into the venous capillaries results in lymph escaping from the surface of the heart into the pericardial sac.^{12,13}

Studies in cardiac surgery

There has been little research by heart surgeons into the role of cardiac lymphatics. Servelle *et al.*¹⁴ intraoperatively injected Evans blue dye into the myocardium and defined the lymphatic collecting system on the surface of the heart and its mediastinal extensions. Caro *et al.*¹³ described cardiac lymphatic anatomy and defined its mediastinal drainage pathways in some patients. They also described cardiac lymph nodes and lymphatic drainage from the pericardial sac during experimental obstruction of lymphatics. It is commonly observed by heart surgeons that cardiac lymph, which is a clear fluid during beating heart surgery, becomes blood-stained, with the highest lactate concentrations after ischaemic cardiac arrest, once the aortic cross-clamp is released; this blood-stained

fluid leaks from the dissected aortic fat pad after cross-clamp release. In 1972, Ullal⁸ conducted several interesting experiments on animals using cardiopulmonary bypass with and without aortic cross-clamping (cardiac arrest/beating heart) and described the timing of microscopic changes within the myocardium caused by chronic lymph outflow blockage. Most of the work on lymphatics in recent years has been carried out either by physicians with a passion for lymphatics, such as Miller¹ at Northwestern University Medical School, or non-clinicians. A significant contribution towards elucidation of lymphatic anatomy of the conduction tissue of the heart was made by Golab³ from Lodz in Poland and Eliska and Eliskova⁷ from Charles University in Prague. Their work and drawings have helped in visualizing sites of possible intraoperative injury of cardiac lymphatics (Figs 2,3).

Atrial fibrillation

Postoperative AF is one of the most common complications after cardiac surgery, occurring within the first week postoperatively in up to 64% of patients.¹⁵ Despite the improvement in myocardial preservation and surgical techniques, AF may remain for years and has a significant influence on patient recovery and hospital resources.¹⁶ The annual estimated US expenditure to treat postoperative AF exceeds \$1bn.¹⁷ Several risk factors for development of postoperative AF have been considered, including age, postoperative withdrawal of beta-blockers, functional atrial ischaemia, prolonged preoperative P-wave duration, cardiopulmonary bypass, postoperative catecholamine use, inadequate protection of right atrial tissue during aortic cross-clamping and histopathological changes in the right atrium. However, it is still difficult to explain why some patients develop AF whereas others with the same risk factors do not.¹⁸ The answer seems to lie in the anatomy, as shown in Figures 1 and 2. Coronary bypass surgery requires removal from the ascending aorta of adventitial tissue and the aortic fat pad, which contains the SA node lymphatic collector, an anatomical detail not widely acknowledged. Once the SA node collector is damaged, it causes impairment of lymphatic drainage from the SA node, leading to dysfunction of the SA node. In addition, a cross-clamp applied to both the aorta and MPA obstructs the entire lymphatic drainage from the heart and thus affects the conduction system of the heart. Most patients with AF have their heart rhythm stabilized and converted to sinus rhythm within the first postoperative week, but AF may lead to cardiac instability and prolonged hospital stay. Postoperative AF is associated with an increased incidence of stroke, hospitalization in intensive care, postoperative ventricular tachycardia or fibrillation and need for placement of a permanent pacemaker.¹⁵ Long aortic cross-clamp time is a risk factor associated with an increased incidence of postoperative atrial arrhythmias.¹⁵ In patients undergoing off-pump coronary artery bypass grafting, the incidence of AF is significantly reduced.¹⁹ A probable advantage of off-pump surgery is that the aortic cross-clamp is not used so there is no obstruction of the right lymphatic trunk that collects lymph from the SA node (Fig. 2).

Fontan procedure

The Fontan procedure is frequently used in patients with various forms of complex congenital heart defects. It separates the systemic circulation from the pulmonary circulation, so venous return from the superior and inferior venae cavae goes directly to the lungs and not to the heart. In one of the Fontan stages, the MPA is transected and the pulmonary valve is over-sewn (Fig. 3). This may result in disruption of the entire lymphatic drainage from the heart as both principal lymphatic trunks are incorporated in the adventitia of the MPA. Cardiac lymphostasis appears to be responsible for some of the complications observed after the Fontan procedure. In some patients, the swollen heart caused by the procedure requires the chest to be left open for a few days for the heart to shrink to its preoperative size. Heart block, a wide range of supra-ventricular and ventricular bradycardias, tachyarrhythmias (including AV junctional rhythm and possible injury to the LPLT) and prolonged pericardial or pleural effusions are also frequently observed in these patients. As patients with early arrhythmia probably have prolonged pleural and/or pericardial effusion, there is clearly an association between conduction tissue damage and lymphatic injury during the procedure. Lymphatic endothelial changes and lymphostasis in endomyocardial biopsy specimens have been observed in patients with a humoral type of rejection.

Conclusions

The aortic fat pad contains a lymphatic collector that drains the SA node. During cardiac surgery, the aortic fat pad should be preserved to avoid impairment of SA node lymphatic drainage, as this may negatively affect node function and trigger postoperative AF. Preservation of the main lymphatic collectors (both principal lymphatic trunks) during the Fontan procedure should reduce the incidence of postoperative arrhythmias and troublesome effusions. Lymphatic drainage of conduction tissue is overlooked, but is a clinically important part of heart anatomy.

Acknowledgements

I acknowledge with gratitude the guidance and invaluable help of Dr Jillian Tatham, Assistant Editor, *ANZ Journal of Phlebology*, Sydney; the encouragement and support of Dr Louis Loizou, Phlebologist, Vein Solutions, Melbourne; and Dr Denis Friedlander, Cardiologist, Waikato Hospital, Hamilton, New Zealand.

References

1. Miller AJ. *Lymphatics of the Heart*. New York: Raven Press, 1982.

2. Verrier RL, Zhao SX. The enigmatic cardiac fat pads: critical but underappreciated neural regulatory sites. *J. Cardiovasc. Electrophysiol.* 2002; **13**: 902–3.
3. Golab B. Lymphatic vessels of the conducting system of human heart. *Folia Morphol. (Warsz)* 1977; **36**: 317–22.
4. Cummings JE, Gill I, Akhrass R, Dery M, Biblo LA, Quan KJ. Preservation of the anterior fat pad paradoxically decreases the incidence of postoperative atrial fibrillation in humans. *J. Am. Coll. Cardiol.* 2004; **43**: 994–1000.
5. Roberts JT. Histology of the heart. The conduction system. In: Luisada AA (ed.). *Development and Structure of the Cardiovascular System*. New York: McGraw-Hill, 1961; 71–84.
6. Uhley HN, Leeds SE, Sung MA. Lymphatic drainage from the ventricular septum to the atrioventricular node in human beings. *J. Am. Coll. Cardiol.* 1983; **1**: 1119–22.
7. Eliska O, Eliskova M. Lymphatic drainage of the ventricular conduction system in man and in the dog. *Acta Anat. (Basel)* 1980; **107**: 205–13.
8. Ullal SR. Cardiac lymph and lymphatics. Experimental observations and clinical significance. *Ann. R. Coll. Surg. Engl.* 1972; **51**: 282–98.
9. Zerbino DD, Gavriash AS. Transformation in the lymphatic system of the heart and myocardium in congestion with lymph. *Arkh. Patol.* 1975; **37**: 30–35.
10. Lupinski RW. Lymphatic aneurysm of the heart. *Lymphology* 2004; **37**: 141–50.
11. Földi M, Casley-Smith JR, Arnold W. *Lymphangiology*. New York: FK Schattauer, 1983.
12. Servelle M, Nogues C. *The Chyliferous Vessels*. Paris: Expansion Scientifique Francaise, 1981.
13. Caro DM, Berjon A, Teijeira J, Duran CG. Anatomical study of the cardiac lymphatics. Their pathogenic role in pericardial effusions. *Ann. Chir. Thorac. Cardiovasc.* 1972; **11**: 373–6.
14. Servelle M, Andrieux J, Cornu C, DeLoche A, Nussaume O. The lymphatics of the heart (peroperative injections). *Arch. Mal. Coeur Vaiss.* 1967; **60**: 89–106.
15. Creswell LL, Schuessler RB, Rosenbloom M, Cox JL. Hazards of postoperative atrial arrhythmias. *Ann. Thorac. Surg.* 1993; **56**: 39–49.
16. Aranki SF, Shaw DP, Adams DH *et al.* Predictors of atrial fibrillation after coronary surgery. Current trends and impact on hospital resources. *Circulation* 1996; **94**: 390–97.
17. Steinberg JS. Postoperative atrial fibrillation: a billion-dollar problem. *J. Am. Coll. Cardiol.* 2004; **43**: 1001–3.
18. Ak K, Akgun S, Tecimer T *et al.* Determination of histopathologic risk factors for postoperative atrial fibrillation in cardiac surgery. *Ann. Thorac. Surg.* 2005; **79**: 1970–75.
19. Ascione R, Lloyd CT, Gomes WJ, Caputo M, Bryan AJ, Angelini GD. Beating versus arrested heart revascularization: evaluation of myocardial function in a prospective randomized study. *Eur. J. Cardiothorac. Surg.* 1999; **15**: 685–90.